

Bioscientia Medicina: Journal of Biomedicine & Translational Research

Journal Homepage: www.bioscmed.com

Colonoscopy Finding: Pseudomembranous Colitis in Chronic Kidney Disease Patient

Ety Febrianti^{1*}, Vidi Orba Busro¹, Suyata¹

¹Department of Internal Medicine, Faculty of Medicine, Universitas Sriwijaya/Dr. Mohammad Hoesin General Hospital, Palembang, Indonesia

ARTICLE INFO

Keywords:

Colonoscopy
End-stage kidney disease
Pseudomembranous colitis

*Corresponding author:

Ety Febrianti

E-mail address:

etyyanti@gmail.com

All authors have reviewed and approved the final version of the manuscript.

<https://doi.org/10.37275/bsm.v8i5.996>

ABSTRACT

Background: Gastrointestinal symptoms are common among patients with chronic kidney disease, reported in up to 70%–80% of patients with end-stage kidney disease. Several factors are involved in the pathogenesis, including the accumulation of uremic toxins and intestinal flora changes. Pseudomembranous colitis is a manifestation of severe colonic disease that is usually associated with *Clostridium difficile* infection but can be caused by a number of different etiologies. Pseudomembranous colitis occurs when changes in the fecal flora allow *Clostridium difficile* overgrowth. Gut dysbiosis, an alteration of the composition and function of gut microorganisms, is commonly seen in patients with chronic kidney disease.

Case presentation: This scientific report presents a case study of a 31-year-old woman diagnosed with pseudomembranous colitis and end-stage chronic kidney disease on hemodialysis. The colonoscopy showed yellow-white nodules that formed pseudomembranes, which were scattered between the edematous mucosa. The patient had been treated with metronidazole for 4 days, but there were side effects. The antibiotic was switched to meropenem for 6 days based on feces culture. The evaluation of colonoscopy result was normal. **Conclusion:** Pseudomembranous colitis is an inflammatory bowel condition most commonly caused by *Clostridium difficile* infection. The presence of pseudomembranous visualization in colonoscopy can significantly establish the diagnosis.

1. Introduction

Colitis is acute or chronic inflammation that affects the colon. Based on the cause, colitis can be divided into infectious and non-infectious colitis. Infectious colitis is divided into amebic colitis, shigellosis, tuberculous colitis, and pseudomembranous colitis. Non-infectious colitis consists of ulcerative colitis, Crohn's disease, radiation colitis, ischemic colitis, microscopic colitis, and non-specific colitis. The colitis most often found in tropical areas such as Indonesia is infectious colitis. The prevalence of amebic colitis in tropical areas is 50-80%. However, the prevalence of shigellosis, tuberculous colitis, pseudomembranous

colitis, and non-specific colitis in Indonesia is not known with certainty. This happens because studies on the epidemiology of colitis in Indonesia are still rarely carried out. Diagnosis of colitis is confirmed through history taking, physical examination, and supporting examinations. However, the clinical symptoms of infectious colitis can be similar to those of Crohn's disease or ulcerative colitis. Therefore, supporting examinations in the form of a colonoscopy are needed to confirm the diagnosis.¹⁻³

The human gastrointestinal system is home to most microbes, such as gut microbiota. In conditions of dysbiosis (a condition of imbalance in the microflora population in the gastrointestinal tract),

the microflora can cause various health problems. Disruption of the balance of the microbiota (dysbiosis) in the gastrointestinal tract is associated with various diseases, including pseudomembranous colitis. Advances in the science and engineering of intestinal microbial populations have become a very interesting topic recently, especially when linked to various diseases such as chronic kidney disease.⁴⁻⁷

2. Case Presentation

A woman, Mrs. R, 31 years old, from Palembang, came to the emergency room at Dr. Mohammad Hosein General Hospital Palembang with complaints of diarrhea 1 month before entering the hospital. The patient also had given birth (postpartum) in 1 month. Approximately 3 months before admission to the hospital, when she was 6 months pregnant, the patient went to a private obstetrician's practice and had her blood pressure checked with a BP result of 195/100. There are no complaints of dizziness and headaches. There is no weakness, no nausea or vomiting. There is no shortness of breath. There is no diarrhea. There is no fever. Both lower legs are swollen. The patient was referred to Dr. Mohammad Hoesin General Hospital and treated. When being treated, the patient was explained to have kidney problems and was consulted by the Internal Medicine Department and advised to undergo dialysis, but the patient was not ready. Then, the patient was outpatient with the anti-hypertension medication methyl dopa 2x1 tab and nifedipine 1x10 mg.

Approximately 2 months before admission to the hospital, the patient complained that both lower legs were becoming increasingly swollen. Her body feels weak. There is no shortness of breath. The patient was readmitted and received a blood transfusion. The patient was educated on dialysis and was still not ready. At approximately 1 month to 8 months of pregnancy, the patient was treated again. The patient complains of shortness of breath and body weakness, and both lower legs becoming increasingly swollen. The patient was advised to terminate the pregnancy with a caesarean section and undergo dialysis. The

patient is willing to undergo dialysis. One day after surgery the patient began to complain of diarrhea, frequency 3-4 x/day, slimy and smelly but not bloody. There are no lumps or sores on the anus. The stomach feels tight and painful. Nausea is there. Vomiting is absent. There is no fever. Decreased appetite. The patient was treated for approximately 10 days, and the shortness of breath and body weakness decreased. No cough. Diarrhea is still there but has been reduced. Patients can be outpatients. Routine dialysis continues at another hospital.

One week after being outpatient, the patient was treated again because of shortness of breath, weakness, and increased diarrhea 4-7 times/day, smelly and slimy. Stomach pain and cramps. Nausea and vomiting are absent. There is no fever. The patient explained that there was fluid in the lining of the heart. After several days of treatment, shortness of breath and weakness decreased, diarrhea was still present, and outpatient treatment and routine control were allowed. The patient is taking captopril. There is no history of surgery other than cesarean section. There is no history of miscarriage. History of known antibiotic use: co-trimoxazole. Physical examination, the general condition was found to be moderately ill, sensorium compos mentis, with BP 136/95 mmHg, pulse 110 x/minute, regular, sufficient tension, respiration 20 x/minute, SpO₂ 99%, temperature 36.1⁰ C, BW 43 kg, TB 148 cm. Body mass index (BMI) 19.5 kg/m². Abdomen: convex inspection, soft palpation, normal turgor, no tenderness, liver and spleen not palpable, percussion: no shifting dullness, increased bowel sounds on auscultation. Laboratory examination hemoglobin 9.9 g/dl, leukocytes 32.85 10³/mm, urea 73 mg/dl, creatinine 7.11 mg/dl. Faeces brown, liquid consistency, leukocytes 2-3, bacteria (++) , occult blood (+).

A colonoscopy revealed edematous, hyperemic mucosa and yellowish plaque with fragile walls and bleeding easily, consistent with the picture of pseudomembranous colitis. Histopathological examination showed that the mucosa was lined with single-layer columnar epithelium and goblet cells.

The lamina propria is in the form of powdery edematous fibrocollagen connective tissue with inflammatory cells, lymphocytes, plasma cells,

eosinophils and neutrophils which extends to the muscularis mucosa, among which intestinal crypts are visible. Impression: Non-specific chronic colitis.

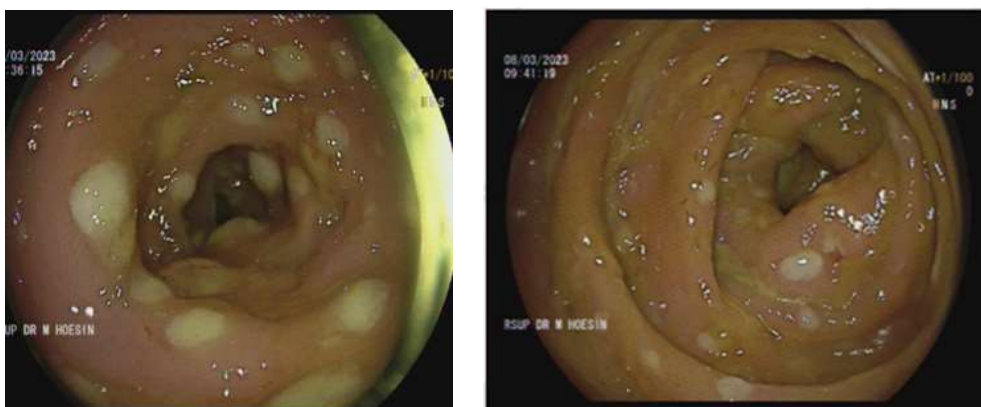


Figure 1. Colonoscopy before therapy.

Clostridium difficile toxin examination could not be implemented, so the author could not determine the cause of pseudomembranous colitis in this patient. During treatment, the patient received intravenous metronidazole 3x500 for 4 days. The patient complained of nausea and vomiting due to the side effects of metronidazole, so on the 5th day of

treatment, the metronidazole was stopped and replaced with intravenous meropenem for 6 days, according to the results of the stool culture. Furthermore, the patient underwent an evaluation colonoscopy on the 10th day of treatment, and the results showed that no pseudomembranous plaque was found.

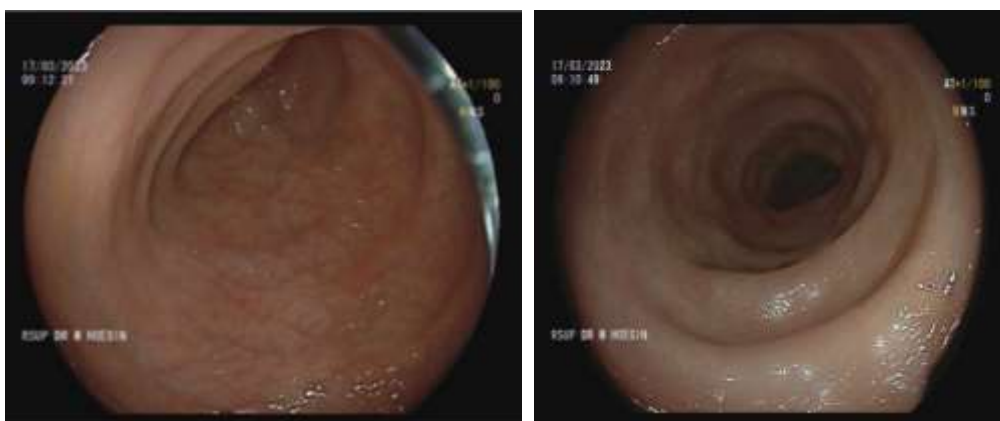

Figure 2. Colonoscopy after antibiotic therapy.

Pseudomembranous colitis is inflammation of the colon due to toxins characterized by the formation of an exudative layer (pseudomembrane) on the surface of the colonic mucosa. Pseudomembranous colitis is also known as antibiotic-associated colitis because it commonly occurs after using antibiotics. However, pseudomembranous colitis can also occur without

prior antibiotic use. About 75-90% of the germs that cause pseudomembranous colitis are *Clostridium difficile*. Pseudomembranous colitis is diagnosed by assessing clinical evaluation, stool testing for enteric pathogens, and visualization of the colonic mucosa via colonoscopy. Symptoms of pseudomembranous colitis are usually associated with watery diarrhea

(99%), fever (29%), abdominal pain (33%) and leukocytosis (61%). Diarrhea is sometimes accompanied by faint blood. Watery diarrhea, abdominal pain, and fever are typical symptoms. Symptoms may appear 1-2 days after starting antibiotics, indicating that changes in colonic flora may develop rapidly. In severe pseudomembranous colitis, there can be an increase in leukocytes $>15,000$ cells/ μL , a decrease in serum albumin <3 g/dL, and an increase in creatinine, which indicates acute kidney failure due to dehydration experienced.

This patient had typical complaints, namely watery diarrhea since 1 day after the cesarean section operation and abdominal pain. Laboratory examination showed leukocytosis ($32,85 \times 10^3/\text{mm}$). The results of blood tests in this patient showed an increase in leukocytes and creatinine. The increase in creatinine in this patient was caused by chronic kidney disease, which had been experienced since ± 3 months ago, not because of acute kidney failure. Colonoscopy is a way to diagnose the presence of pseudomembranes. On colonoscopy examination, pseudomembranous colitis is characterized by raised yellow-white nodules or plaques that form pseudomembranes on the surface of the colonic mucosa. The eruption of neutrophils and other inflammatory elements from the lamina propria onto the epithelium then causes pseudomembrane formation. Pseudomembranes measuring 2-10 mm in diameter are scattered between normal or erythematous mucosa, but confluent pseudomembranes covering the entire mucosa can be seen in severe pseudomembranous colitis.

The results of this patient's first colonoscopy showed yellow and white nodules forming pseudomembranes scattered between the mucosa. The mucosa appears hyperemic and edematous. When a biopsy was performed on the nodule, it looked fragile. After antibiotic therapy, the patient underwent an evaluation colonoscopy and obtained a normal colonic image. This patient also suffers from chronic kidney disease and has been undergoing hemodialysis for 1 month. The patient has risk factors

for pseudomembranous colitis, namely uremia, history of caesarean section surgery, and history of being hospitalized before diarrhea symptoms appeared $\pm 4x$. The only known history of antibiotic use is co-trimoxazole. Patients with advanced chronic kidney disease often have a variety of gastrointestinal symptoms, such as anorexia, nausea, and vomiting. Because these symptoms are common in patients with end-stage kidney disease and are usually associated with uremia colonic changes in these cases are sometimes undiagnosed.

3. Discussion

Chronic kidney disease is associated with dietary restrictions, slow colonic transit, changes in the biochemical environment of the digestive tract, and the use of certain medications such as antibiotics, phosphate binders, and iron-containing compounds. All these factors contribute to the development of gut dysbiosis in chronic kidney disease patients. Chronic kidney disease sufferers are characterized by decreased consumption of fiber foods. Indigestible carbohydrates are essential nutrients for the saccharolytic microbiota and the reduction of these substrates results in decreased production of short-chain fatty acids. Lack of dietary fiber causes an increase in amino nitrogen which can be converted into uremic toxins by the intestinal microbiota. Chronic kidney disease sufferers are characterized by an imbalance between saccharolytic (fermentative) and proteolytic (putrefactive) microbiota. Imbalances have detrimental effects on the development of chronic kidney disease.⁸⁻¹⁰

In patients with chronic kidney disease, prolonged colonic transit can cause an increase in the number of proteolytic species that contribute to an imbalance between saccharolytic and proteolytic microbiota. This results in increased production and absorption of the end products of bacterial protein fermentation. Urea is a waste product that accumulates in people with chronic kidney disease. Increased urea into the intestinal lumen causes overgrowth of urease-expressing bacteria. Hydrolysis of urea by intestinal

microbes results in the formation of large amounts of ammonia. Ammonia increases the pH of the intestinal lumen and changes microbiota composition, which leads to dysbiosis. Patients with chronic kidney disease generally receive antibiotics to treat vascular access and other infections. The use of antibiotics results in a decrease in the number of important gut microbiota needed to maintain homeostasis, loss of biodiversity, changes in metabolism, and expansion of pathogens. On the other hand, long-term consumption of phosphate binders and iron-containing compounds can cause changes in the luminal environment of the digestive tract and affect the microbial flora, thereby causing dysbiosis.¹¹⁻¹⁶

This patient was treated as pseudomembranous colitis suspected of being caused by *Clostridium difficile* infection. After receiving antibiotic therapy with metronidazole 3x500 mg infusion for 4 days and continued administration of meropenem 1x500 mg injection (dose adjustment) for 6 days, clinical improvement and improved colonoscopy images were obtained. The clinical response to therapy is improvement in diarrhea within 1-4 days after antibiotic administration, with resolution within 2 weeks. Recurrence of diarrhea is a difficult clinical problem and occurs in 10-50% of cases with an overall recurrence risk of approximately 20%.¹⁷⁻²⁰

4. Conclusion

Pseudomembranous colitis is an inflammatory condition of the colon that is most often caused by *Clostridium difficile* infection. The presence of pseudomembrane visualization on colonoscopy can significantly confirm the diagnosis. Chronic kidney disease predisposes to loss of balance in the intestinal microbial flora (dysbiosis) and on the other hand, intestinal dysbiosis influences the development of chronic kidney disease.

5. References

1. McDonald LC, Kelly CP, Gower RM, Barnes DM, Tosolow AA, Chang T. *C difficile* colitis. Ann Intern Med. 2023; 103(6): 864-72.
2. Kelly CP, LaMont JT, Lindell VM. *Clostridium difficile*-associated diarrhea in adults and children. Clin Infect Dis. 2022; 18(4): 775-82.
3. Bartlett JG. *Clostridium difficile*: more than just a cause of pseudomembranous colitis. Rev Infect Dis. 2023; 12(Suppl 1): S157-63.
4. Zar FL, Bakri MM, Rao SM. A comparison of vancomycin and metronidazole for the treatment of pseudomembranous colitis caused by *Clostridium difficile*. N Engl J Med. 2023; 318(2): 161-7.
5. Kyne L, Willoughby J, Mullany H. Guidelines for the diagnosis, treatment and prevention of *Clostridium difficile* infection. Ir Med J. 2023; 110(7): 828.
6. McDonald LC, Gerding DN, Chapin EK. Current practices of diagnosing *Clostridium difficile* infection (CDI). Clin Infect Dis. 2022; 41(Suppl 1): S180-8.
7. Poutanen SM, Micic D, Douketis JD. Diagnosis and treatment of *Clostridium difficile* infection. CMAJ. 2022; 190(48): E1358-66.
8. Deshpande A, Sunkara B, Khanna S. Fidaxomicin vs vancomycin for initial treatment of *Clostridium difficile* infection. JAMA. 2022; 303(17): 1717-25.
9. Louie RE, Miller MH, Mullane KM. Fidaxomicin versus vancomycin for *Clostridium difficile* infection: superiority of fidaxomicin against infection recurrence. Clin Infect Dis. 2021; 53(3): 239-45.
10. Zúñiga AA, Khanna S, Bhambhani S. Bezlotoxumab for prevention of recurrent *Clostridium difficile* infection. N Engl J Med 2023; 377(7): 655-64.
11. Cornely TA, Crook DW, Louie TJ. Tofacitinib versus vancomycin for multicentric *Clostridium difficile* infection. N Engl J Med.

- 2022; 379(25): 2391-400.
12. Lessa MC, Gould CV, McDonald LC. Current status of *Clostridium difficile* infection in North America. Clin Infect Dis. 2022; 61(4): 479-85.
 13. Khanna S, Aronoff DM, Dryden VM. Global epidemiology of *Clostridium difficile* infection: a systematic review and meta-analysis. Clin Infect Dis. 2022; 64(7): 988-1000.
 14. Louie TJ, Miller MH, Arias CA, Connor BA, Dilella LA, Flaherty V. Clinical Practice Guidelines for *Clostridium difficile* infection in adults: 2017 Update by the Infectious Diseases Society of America (IDSA) and Society for Healthcare Epidemiology of America (SHEA). Clin Infect Dis. 2022; 65(2): 165-80.
 15. Poutanen SM, Micic D, Douillière M, Flament C, Greco MF, Hernández-Romero P. *Clostridium difficile* infection in healthcare settings: a European perspective. Lancet Infect Dis. 2022; 18(4): e131-e141.
 16. Cohen SH, Gerding DN, Johnson S, Kelly CP, Loo V, Macdonald CL. Clinical Practice Guidelines for *Clostridium difficile* infection in adults: 2023 Update by the Society for Healthcare Epidemiology of America (SHEA) and the Infectious Diseases Society of America (IDSA). Clin Infect Dis. 2023; 56(4): e27-e80.
 17. McDonald LC, Gerding DN, John S, Loo V, McGlone S, Mellow MH. American College of Gastroenterology Clinical Guideline: Management of *Clostridium difficile* infection. Am J Gastroenterol. 2023; 109(11): 1623-46.
 18. Deshpande A, Sunkara PS, Khanna S. Diagnosis of *Clostridium difficile* Infection. Curr Gastroenterol Rep. 2022; 20(11): 68.
 19. Lessa MC, Gould CD, McDonald LC, Angulo FJ, Orozco MM, Reed JC. Burden of *Clostridium difficile* infection in the United States. Emerg Infect Dis. 2022; 21(8): 1597-600.
 20. Khanna S, Pardi DS, Khanna P. Diagnosis and management of pseudomembranous colitis. May Clin Proc. 2020; 85(8): 805-12.